

Indwelling Tunnelled Pleural Catheters: Practical Aspects

Helen DAVIES MD¹, YC Gary LEE MD²

¹ Research Fellow in Pleural Disease, Oxford Centre for Respiratory Medicine, Oxford, UK

² Consultant & Senior Lecturer, Oxford Centre for Respiratory Medicine and University of Oxford, UK
Research Team Leader, Centre for Respiratory Research, University College London, UK

e-mail: hedavies@doctors.net.uk

INTRODUCTION

Insertion of a chronic indwelling pleural catheter (IPC), or tunnelled pleural catheter (TPC), for pleural effusion refractory to first-line therapeutic manoeuvres (1,2), is becoming more widely accepted in clinical practice.

INDICATIONS

1. Malignant Pleural Disease

The main indication for IPC insertion is recurrent symptomatic malignant pleural effusion and failed pleurodesis, or underlying “trapped lung”. Pleural effusions commonly complicate malignant disease and are a major source of patient morbidity, adversely affecting quality of life often during the terminal phases of illness. Drainage of pleural effusion can relieve symptoms such as dyspnoea, cough or chest pain however invariably pleural fluid re-accumulates and further

pleural intervention is required³. Attempted pleurodesis with sterile talc is accepted by most pulmonologists (4) as the strategy of choice to prevent fluid recurrence but in 10-40% of cases is unsuccessful (5-11). Treatment options for these patients are limited. Serial thoracenteses can be performed but procedural discomfort, and accompanying risks of pleural infection and pneumothorax should limit this approach to patients with poor expected survival rates. Repeat pleurodesis is associated with a lower success rate (approximately 50%) (6), and surgical techniques (parietal pleurectomy or formation of a pleuroperitoneal shunt) are rarely suitable for patients with terminal malignant disease and reduced functional status.

Insertion of an IPC in this patient cohort offers an out-patient based solution favourable to patients and physicians alike.

2. Chronic Pleural Infection

Case reports of successful treatment of chronic pleural infection with indwelling pleural catheters have been documented by our group (12). However, at present judicious use in selected patients is appropriate and more data assessing this role of the IPC is needed.

3. Chylothorax

Jimenez et al described the use of the IPC in 19 patients with recurrent symptomatic chylothorax in association with cancer relapse (13). No major complications were encountered and the authors conclude that IPC insertion is a viable option in the palliative management of resistant chylothorax.

CONTRAINDICATIONS

Few absolute contraindications to IPC insertion exist however the following points should be borne in mind:

- Definite improvement in patient symptoms should always be demonstrated from pleural fluid evacuation in all patients prior to IPC consideration, especially in patients with significant co-morbidities where presence of a pleural effusion may not be the sole contributor to patients' breathlessness (e.g. concomitant lymphangitis carcinomatosa or obstructive airways disease).
- In those with a poor performance status / short predicted survival (< 4-6 weeks) repeated palliative thoracenteses are preferable.
- Coagulopathies should be corrected.
- Individuals with severe skin pathology overlying the favoured implantation site (e.g. tumour invasion / psoriasis), should receive alternative treatment to relieve symptoms.
- Immunodeficiency states indicate a need for caution to minimise the risk of secondary pleural infection. Insertion should ideally be delayed until completion of chemotherapy and optimisation of underlying defective conditions.

- Informed consent from patients should incorporate post-procedure care of the IPC. Those who are unwilling, or unable, to manage a catheter and do not have appropriate medical support should not proceed.
- Chylothorax, pleural infection and multi-loculated collections remain relative contraindications.

Catheter Placement

IPC insertion is performed as a day case thereby avoiding hospital admission. Clinical examination, platelet count and coagulation studies, and appropriate imaging should be completed, with informed consent obtained prior to the procedure. Complications which should be covered whilst attaining consent are described below.

Figure 1 shows the equipment required.

A systematic stepwise approach should be followed:

1. Lay the patient in a lateral decubitus position with the affected hemithorax uppermost.
2. Conscious sedation with midazolam and/or fentanyl may be required for some patients.
3. Thoroughly clean the hemithorax, axilla and upper arm with a sterilizing preparation e.g. chlorhexidine.
4. Infiltrate local anaesthetic and locate pleural fluid with standard thoracocentesis in the mid axillary line.
5. Using the Seldinger technique pass the guide-wire into the pleural space at this site.
6. Make a 0.5-1cm subcutaneous incision horizontally adjacent to the wire.
7. Insert local anaesthetic (with adrenaline if available) subcutaneously from this incision inferomedially approximately 5 cm and make a second horizontal incision-this will be the exit port for the IPC. To minimise female patients' discomfort and inconvenience this site should be below the bra line.

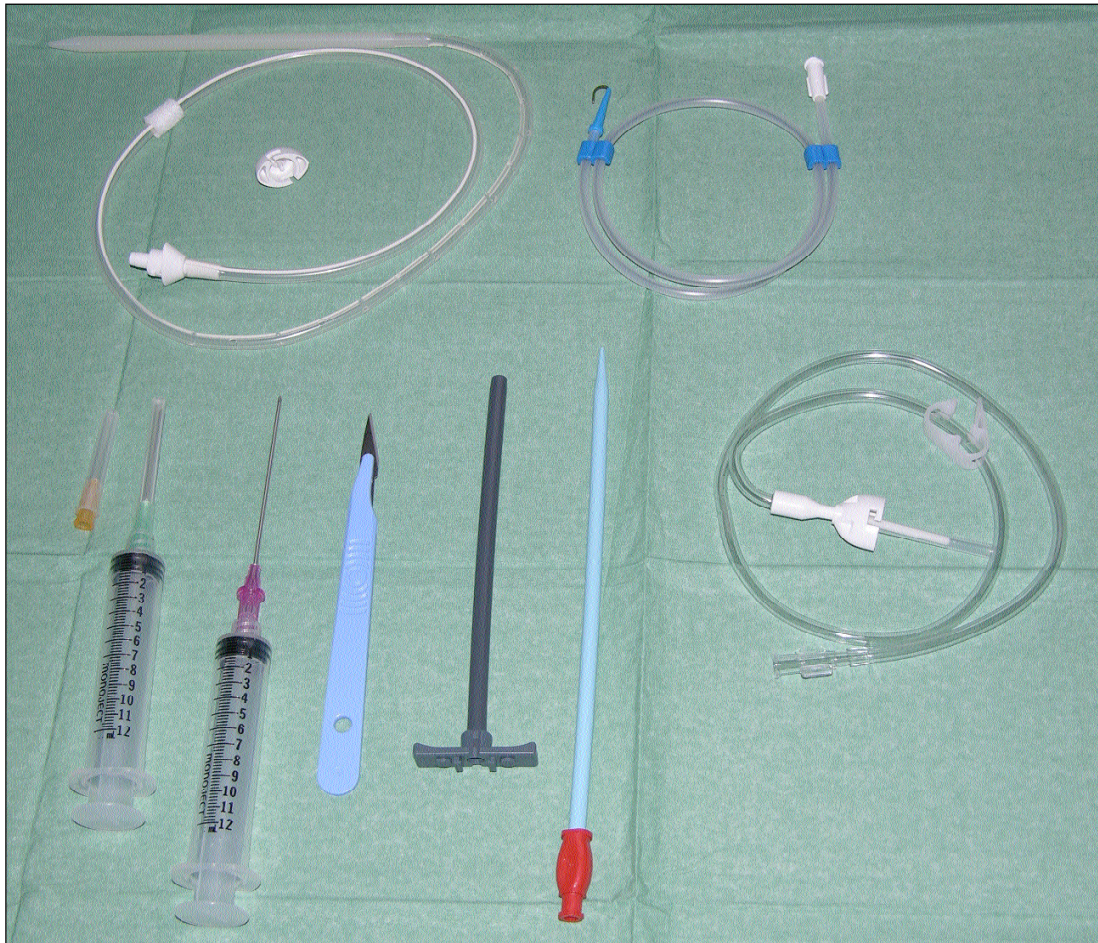

Figure 1. Equipment required for ambulatory indwelling pleural catheter insertion.

8. Create a tunnel for the IPC by dissecting subcutaneously between the incisions using a blunt forceps.
9. Guide the trocar (attached to the IPC) through the tunnel and pull the catheter out next to the guide-wire so that the polyester cuff lies midway within the track.
10. Dilate the guide-wire track using the dilator and Teflon 'peel-away' sheath.
11. Leaving the sheath in place remove the dilator and guide-wire.
12. Feed the fenestrated catheter through the sheath into the pleural space withdrawing the "peel-away" sheath simultaneously.
13. Gently pull the proximal end of the IPC to straighten any kinks around the insertion site.
14. Place one suture over the mid axillary line incision and secure the medial end with another non-absorbable suture and sterile dressing.
15. After catheter insertion pleural fluid can be drained immediately and a chest roentogram requested.

Post Insertion Care

Outpatient care of an IPC is usually by patients and their families/carers. Education about what an IPC is, how and when to use it, and when to notify the doctor is crucial to maximise the benefits, and promptly address any concerns. Full written and pictorial instructions should be given to all caregivers and reviewed prior to initial drainage. A programme of training overseen by a healthcare professional (usually requiring 2 day case visits) is recommended prior to unsupervised drainage at home.

Although IPC use is associated with significant short-term (7 day) healthcare cost benefits compared to inpatient care (14,15), the long-term

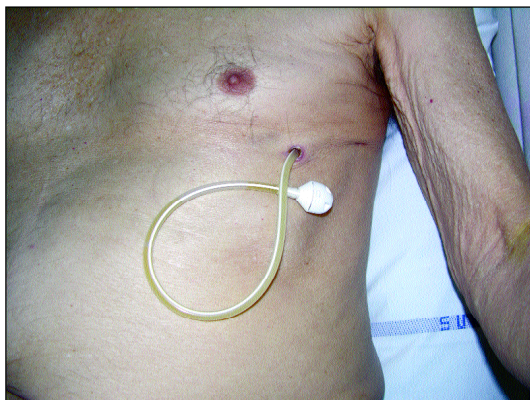


Figure 2. Indwelling pleural catheter in situ.

economic implications have not been formally assessed. A potential transfer of costs from the hospital inpatient to the outpatient, primary care, setting, may be predicted as expenses are encountered from supplementary drainage equipment (e.g. bottles, dressing packs, catheter caps etc) and support for the patient at home. A comprehensive analysis of the comparative costs associated with use of the IPC and other modalities is required.

Complications

No mortality has been reported related to IPC placement or use and overall associated morbidity rates are low.

Complications which have been reported in the literature are summarised in (Table 1).

Indwelling catheters without a polyester cuff (which is designed to secure the catheter in position and prevent pleural infection) have previously been used; however no studies comparing the complication rates of cuffed and non-cuffed catheters have been performed.

Commonly Asked Questions

- *Can the IPC be removed? When would you consider IPC removal?*

Yes, IPC removal is performed as a day case and is considered when no pleural fluid has been obtained for 6 weeks, and imaging shows no significant

Complication	Frequency (%)	References
Pleural infection	1 – 18	14-20
Catheter blockage	3 – 18*	15;16;18;20
Catheter displacement	1.2 – 3	17;19
Tumour tracking	0.4 – 3	15;17-19
Skin cellulitis	11	14;16;18;19
Effusion recurrence (needing intervention)	4 – 11	14;15;19
PTX/BPF / SC air	2.4	19

* Complicated by catheter rupture in one patient (16).
 PTX: Pneumothorax, BPF: Bronchopleural fistula, SC: Subcutaneous.

residual fluid. This most commonly occurs as a result of spontaneous pleurodesis (see below). In patients with ipsilateral empyema who fail to respond to antibiotic therapy, catheter misplacement or a failure to achieve symptomatic improvement from an IPC, removal should be considered.

Local anaesthetic should be infiltrated along the subcutaneous catheter tunnel and blunt dissection used to release the polyester cuff. The catheter can then be carefully withdrawn.

- *What is the spontaneous pleurodesis rate associated with IPC?*

Spontaneous pleurodesis occurs in between 21-70% (13-15,17-19-21) and is determined by a failure to obtain pleural fluid despite catheter patency with confirmation using sequential imaging assessment.

- *Is it safe for patients to receive chemotherapy with an IPC in situ?*

Yes, however it is routine practice in our hospital to recommend a short interval (arbitrarily 3 weeks) between IPC insertion and institution of chemotherapy. This advice aims to minimise the risk of intrapleural or skin infection associated with the nadir of potential iatrogenic bone marrow suppression.

- *Is IPC site palliative radiotherapy required for patients with mesothelioma?*

Prophylactic radiotherapy will not, at least in theory, protect against the ongoing risks of catheter metastases posed by the presence of IPC and the associated constant breach of the parietal pleura. Non randomised data report rates of catheter-tract metastases between 0.4 and 7% for IPCs (15,17-19,22). Local external beam radiotherapy can be safely applied to the site of the catheter, if and when symptomatic catheter-tract metastases occur, with no functional interference to catheter drainage.

- *Is there any survival advantage associated with IPC use?*

No statistically significant change in life expectancy, in patients with malignant pleural disease, has been shown with IPC use however; evidence does suggest that patients' quality of life is improved compared with chest drain insertion and pleurodesis¹⁸. The use of indwelling catheters as first-line treatment for malignant pleural effusion is currently being assessed in a randomised controlled trial sponsored by the British Lung Foundation.

SUMMARY

Indwelling pleural catheters are safe and provide a valuable alternative to repeated thoracenteses for patients with refractory malignant pleural effusions. The role of the IPC in the treatment of non-malignant pleural conditions, and as a first line treatment for malignant effusions, requires further research.

REFERENCES

1. Davies HE, Lee YCG. Pleurodesis. In: Light RW, Lee YCG (eds). *Textbook of Pleural Diseases*. London: UK: Arnold Press (in press), 2008.
2. West SD, Davies RJ, Lee YC. Pleurodesis for malignant pleural effusions: Current controversies and variations in practices. *Curr Opin Pulm Med* 2004; 10: 305-10.
3. Anderson CB, Philpott GW, Ferguson TB. The treatment of malignant pleural effusions. *Cancer* 1974; 33: 916-22.
4. Lee YC, Baumann MH, Maskell NA, et al. Pleurodesis practice for malignant pleural effusions in five English-speaking countries: Survey of pulmonologists. *Chest* 2003; 124: 2229-38.
5. Antunes G, Neville E, Duffy J, Ali N. BTS guidelines for the management of malignant pleural effusions. *Thorax* 2003; 58 (Suppl 2): 29-38.
6. Dikensoy O, Light RW. Alternative widely available, inexpensive agents for pleurodesis. *Curr Opin Pulm Med* 2005; 11: 340-4.
7. Dresler CM, Olak J, Herndon JE, et al. Phase III intergroup study of talc poudrage vs talc slurry sclerosis for malignant pleural effusion. *Chest* 2005; 127: 909-15.
8. Fentiman IS, Rubens RD, Hayward JL. Control of pleural effusions in patients with breast cancer. A randomized trial. *Cancer* 1983; 52: 737-9.

9. Sahn SA. Malignant pleural effusions. *Semin.Respir.Crit Care Med* 2001; 22: 607-16.
10. Ukale V, Agrenius V, Hillerdal G, Mohlkert D, Widstrom O. Pleurodesis in recurrent pleural effusions: a randomized comparison of a classical and a currently popular drug. *Lung Cancer* 2004; 43: 323-8.
11. Yim AP, Chan AT, Lee TW, Wan IY, Ho JK. Thoracoscopic talc insufflation versus talc slurry for symptomatic malignant pleural effusion. *Ann.Thorac.Surg.* 1996; 62: 1655-8.
12. Davies HE, Rahman NM, Parker RJ, Davies RJO. Use of Indwelling Pleural Catheters for Chronic Pleural Infection. *Chest* 2008; (in press).
13. Jimenez CA, Mhatre AD, Martinez CH, Eapen GA, Onn A, Morice RC. Use of an indwelling pleural catheter for the management of recurrent chylothorax in patients with cancer. *Chest* 2007; 132: 1584-90.
14. Musani AI, Haas AR, Seijo L, Wilby M, Sterman DH. Outpatient management of malignant pleural effusions with small-bore, tunneled pleural catheters. *Respiration* 2004; 71: 559-66.
15. Putnam JB Jr, Walsh GL, Swisher SG, et al. Outpatient management of malignant pleural effusion by a chronic indwelling pleural catheter. *Ann.Thorac.Surg.* 2000; 69: 369-75.
16. Pien GW, Gant MJ, Washam CL, Sterman DH. Use of an implantable pleural catheter for trapped lung syndrome in patients with malignant pleural effusion. *Chest* 2001; 119: 1641-6.
17. Pollak JS, Burdge CM, Rosenblatt M, Houston JP, Hwu WJ, Murren J. Treatment of malignant pleural effusions with tunneled long-term drainage catheters. *J Vasc.Interv.Radiol.* 2001; 12: 201-8.
18. Putnam JB Jr, Light RW, Rodriguez RM, et al. A randomized comparison of indwelling pleural catheter and doxycycline pleurodesis in the management of malignant pleural effusions. *Cancer* 1999; 86: 1992-9.
19. Tremblay A, Michaud G. Single-center experience with 250 tunnelled pleural catheter insertions for malignant pleural effusion. *Chest* 2006; 129: 362-8.
20. van den Toorn LM, Schaap E, Surmont VF, Pouw EM, van der Rijt KC, van Klaveren RJ. Management of recurrent malignant pleural effusions with a chronic indwelling pleural catheter. *Lung Cancer* 2005; 50: 123-7.
21. Tremblay A, Mason C, Michaud G. Use of tunnelled catheters for malignant pleural effusions in patients fit for pleurodesis. *Eur Respir J* 2007; 30: 759-62.
22. Janes SM, Rahman NM, Davies RJ, Lee YC. Catheter-tract metastases associated with chronic indwelling pleural catheters. *Chest* 2007; 131: 1232-4.