

# INVASIVE STAGING AND RESTAGING IN NON-SMALL CELL LUNG CANCER

Michèle N. De Waele, Paul E. Van Schil

Department of Thoracic and Vascular Surgery, Antwerp University Hospital, Wilrijkstraat 10, B-2650 Edegem (Antwerp), Belgium

e-mail: mizziedewaele@hotmail.com

doi:10.5152/tcb.2012.22

## Abstract

Bronchogenic carcinoma is the leading cause of cancer related death in Western countries. When a diagnosis of lung cancer is made, staging and restaging are important to determine prognosis and to decide on subsequent therapeutic strategies. Concerning staging of mediastinal lymph nodes in non-small cell lung cancer, a positive result of a noninvasive procedure should be histologically or cytologically confirmed. Minimally invasive techniques are complementary to surgical invasive staging techniques with a high specificity but low negative predictive value. Therefore, an invasive surgical technique is indicated if they yield negative results. If needle aspiration is positive, this result may be valid as proof for N2 or N3 disease. Restaging in non-small cell lung cancer remains a controversial issue. Downstaging of mediastinal lymph nodes determines survival in stage IIIA-B non-small cell lung cancer. Different restaging techniques (noninvasive, minimally invasive and invasive) do exist and the level of concurrent use still has to be further explored. At this moment, minimally invasive techniques are especially useful for primary staging. Mediastinoscopy and repeat mediastinoscopy provide the largest tissue samples. Although remediastinoscopy is technically difficult, it remains of utmost importance as part of the restaging process. For thoracic surgeons having no experience with repeat mediastinoscopy, an alternative approach consists of the initial use of a minimally invasive staging procedure to obtain cytological proof of mediastinal nodal involvement. After induction therapy, patients are subsequently restaged by mediastinoscopy. In this way, a technically more demanding remediastinoscopy can be avoided.

**Key words:** Lung cancer, staging, restaging, prognosis, repeat mediastinoscopy, minimally invasive procedure

## ARTICLE

Lung cancer is the leading cause of cancer related mortality worldwide. It is classified according to histological type. Non-small cell lung cancer (NSCLC) and small cell lung cancer (SCLC) are by far the most prevalent types of lung cancer, accounting for approximately 95% of all bronchogenic carcinomas. There are several subtypes of NSCLC. The three most frequent subtypes of NSCLC are adenocarcinoma, squamous cell carcinoma and large cell carcinoma. Nowadays adenocarcinoma is the most common histological type of lung cancer (1, 2) (Table 1).

When a diagnosis of lung cancer is made, staging is important to determine prognosis. Next to evaluating the primary tumor, the extent of spread to thoracic

and extrathoracic organs determines resectability. Staging of NSCLC is equally important to define treatment options and prognosis. TNM staging is based on the characteristics of the primary tumor (T), the degree of lymph node involvement (N) and the presence or absence of metastasis (M). The combination of T, N and M descriptors are then used to give the tumor an overall stage (I-IV), with the aim of grouping patients into stages with similar prognoses. Treatment options also vary from stage to stage.

When there are no distant metastases, prognosis of a patient with lung cancer mainly depends on locoregional lymph node involvement. In patients with lung cancer, ipsilateral hilar or intrapulmonary lymph node metastases (N1) adversely affect the patient's prognosis but do not generally prohibit resectability.

**Table 1.** Frequencies of histological types of lung cancer

Histological Type	Frequency (%)
Non-small cell lung cancer	80
Adenocarcinoma	40
Squamous cell lung cancer	30
Large cell lung cancer	10
Small cell lung cancer	15
Others	5

Stage I-II disease is mostly treated with surgery and adjuvant chemotherapy when the tumor is >4 cm or when N1 nodes are involved.

Preoperatively documented involvement of N2 mediastinal lymph nodes is an ominous sign for prognosis and is in most centers a contraindication for upfront surgery. Pathological staging remains the gold standard in quantifying the extent of disease. Stage IIIA comprises locoregional disease and is usually treated by sequential or concurrent chemoradiation or induction chemotherapy and/or radiotherapy, followed by surgery if there is proof of mediastinal downstaging. Nowadays, reasonable survival rates have been reported in patients with N2 NSCLC, and therefore patients with limited N2 disease in whom downstaging is obtained after induction therapy, may be surgical candidates. Stage IIIB (N3 involvement) and IV almost never meet the criteria for surgery and are usually treated by chemo- and/or radiotherapy and supportive care (3). According to the revised TNM staging system for NSCLC, 5-year survival rates for the newly defined clinical stages are: IA 50%, IB 46%, IIA 36%, IIB 26%, IIIA 19%, IIIB 7%, and IV 2%. The corresponding 5-year survival rates for their pathologic counterparts are: IA 73%, IB 58%, IIA 46%, IIB 36%, IIIA 24%, IIIB 9%, and IV 13% (4).

### Staging NSCLC

Concerning computed tomography (CT), the only useful criterion to assess malignancy is size. Nodes that have a short axis diameter greater than 1 cm on CT are considered abnormal. The positive and negative predictive value (PPV and NPV) in primary staging of mediastinal lymph nodes on CT are 56% and 83%, respectively (5).

Fluorodeoxyglucose positron emission tomography (FDG-PET) is more accurate than CT for staging mediastinal nodes as it is dependent not only on size but also on metabolic activity. Reported NPV for FDG-PET is 93%, although PPV was only 79% (6). In that

way, a positive FDG-PET would still require tissue confirmation of lymph node metastasis. Tissue will remain the issue for still a considerable period of time as FDG-PET avidity shows metabolic function not exclusively for malignancies alone. Combining FDG-PET and CT is better than CT or PET alone with a high accuracy of 90% and therefore, if available, should be used in the staging process of NSCLC (7). Only a negative CT and negative FDG-PET or PET-CT may obviate the need for mediastinoscopy or minimally invasive techniques prior to surgery.

Minimally invasive techniques comprise promising staging modalities. Unfortunately, high false negative rates have been reported (8, 9). Cerfolio et al. recently published the results of a retrospective review of 234 patients with NSCLC who were staged by endobronchial or oesophageal ultrasound (EBUS or EUS) for suspected N2 disease on CT or PET-CT. A mediastinoscopy was performed when EBUS/EUS was negative. NPV for detecting N2 disease of EBUS, EUS and mediastinoscopy was 79%, 80% and 93% respectively. EBUS was found to be falsely negative in 28% and EUS in 22% (8). In a single institution, retrospective study by Defranchi et al., 494 patients, suspected of lung cancer, underwent EBUS. A negative result was followed by mediastinoscopy. 28% of patients with suspicious mediastinal lymph nodes had N2 disease confirmed by mediastinoscopy despite negative EBUS (9). In this way, negative EBUS/EUS in patients with suspicious mediastinal nodal disease should be confirmed by mediastinoscopy.

The role of surgical mediastinal staging and restaging is a matter of judgement and correct interpretation of staging results. No test, non-invasive, minimally invasive or invasive, can expect to yield perfect results. In that way, it becomes a question of how much certainty one is willing to accept. The decision is influenced by the risk and morbidity of the procedures involved. Mediastinoscopy is associated with low morbidity (2%) and low mortality (0.08%) but is an invasive procedure (10). Right and left high and low paratracheal nodes (stations 2R, 2L, 4R, 4L) and anterior subcarinal nodes (station 7) are accessible via this approach. The reported PPV and NPV as staging procedure in NSCLC are 100% and 91%, respectively (6).

Addition of endoscopic ultrasound with fine needle aspiration to mediastinoscopy has produced some excellent results with a reported increase of sensitivity in detection of mediastinal nodal disease to 93% (11). In the ASTER trial by Annema et al., 241 patients with resectable (suspected) NSCLC, in whom mediastinal

staging was indicated based on CT or PET, were included in a randomized controlled multicenter study. Nodal metastases were found in 35% by surgical staging versus 46% by endosonography (EBUS and EUS) versus 50% by endosonography followed by surgical staging. NPV was 86% versus 85% (p=0.47) versus 93% (p=0.18), respectively.

In conclusion, concerning staging of mediastinal lymph nodes in NSCLC and in concordance with the ESTS guidelines, positive CT, PET, or PET-CT findings should be histologically or cytologically confirmed. EBUS and EUS are complementary to surgical invasive staging techniques with a high specificity but low NPV. Therefore an invasive surgical technique is indicated if they yield negative results. If needle aspiration is positive, this result may be valid as proof of N2 or N3 disease (5).

In Figure 1, a general flow chart, concerning mediastinal staging in NSCLC is provided.

**Restaging NSCLC**

Most patients with pathologically proven N2 disease detected during preoperative work-up will be treated by induction therapy. With induction or neoadjuvant therapy a downstaging of locally advanced tumors is aimed at, together with an eradication of systemic micrometastases.

For locally advanced NSCLC, the major question remains whether a better local control and survival are obtained by induction therapy followed by surgery compared to standard chemoradiotherapy. Concerning N2 patients, studies confirm that mainly patients with initial stage IIIA or IIIB and mediastinal downstaging will benefit from surgical resection.

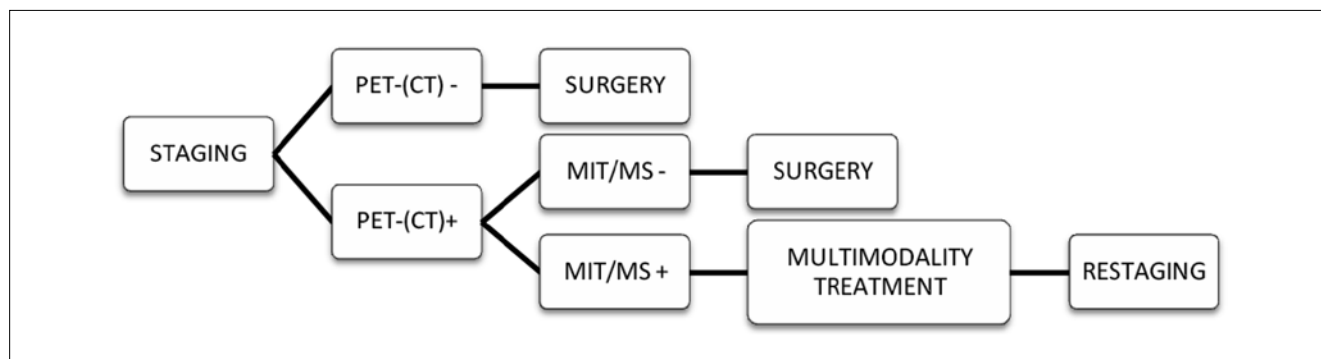
The mediastinum can be principally restaged by the same techniques as applied in primary staging. At the present time, neither CT, PET or PET-CT are accurate enough to make final further therapeutic decisions based on their results.

The accuracy of CT decreases in restaging after induction therapy to 58%. PET scanning is more accurate than CT for mediastinal restaging with reported PPV to detect persisting nodal disease of 73% but less than 20% for residual N2 disease (12). The use of PET-CT fusion images significantly increases the accuracy through better localization of focal FDG uptake in mediastinal nodes. PPV varies between 75-93%. However, 20% false negative and 25% false positive cases have been reported (13). In case of suspicion of residual mediastinal disease, nodal biopsies are still required.

Minimally invasive techniques such as EBUS and EUS comprise promising restaging modalities. However, false negative rates are at least 20-30% (14-16). Therefore, negative findings should still be confirmed by surgical restaging. Rapid on-site cytopathologic evaluation (ROSE) may facilitate the decision of whether to proceed to a second procedure in the same session.

Repeat mediastinoscopy, although technically more difficult than the first procedure, offers the advantage of providing pathological proof of response after induction therapy. The accuracy of this procedure lies between 81-93% (17, 18). Nowadays, restaging is the most frequent indication for reMS but it can also safely be performed for other indications (19). In contrast to imaging or functional studies, reMS offers the advantage of providing a definite diagnosis of varying thoracic diseases involving the mediastinal lymph nodes, but also giving pathological evidence of response after induction therapy.

Following the ESTS guidelines for restaging after induction treatment for NSCLC, neither CT, PET or PET-CT are presently accurate enough to make final further therapeutic decisions based on their results. An invasive technique providing cyto-histological information is recommended. For restaging, endoscopic techniques or surgical invasive techniques can be



**Figure 1.** General flow chart for mediastinal staging in NSCLC

CT: computed tomography; PET: positron emission tomography; MIT: minimally invasive technique (EBUS/EUS); MS: mediastinoscopy

used. If they yield a positive result, non-surgical treatment seems to be indicated in most of the patients. The choice may be dependent on the availability of the technique and expertise of the center (5).

In our series, patients with true positive reMS had a MST of 14 months, in contrast to 28 months in those with true negative reMS. This difference was highly significant ( $p=0.001$ ). We also reported a MST for false negative reMS of 24 months, which is 10 months longer than for those with positive reMS (20). This may indicate that, although micrometastases were found at thoracotomy, surgery may prolong survival when a complete resection can be obtained, probably by slowing down the disease progression. In the combined group of false negative and true negative results, the MST was 27 months and the difference from the positive results remained highly significant ( $p=0.001$ ). In a multivariate analysis, only nodal status was confirmed to be a significant independent prognostic factor for survival. Several studies documented a survival benefit in downstaged patients when a pneumonectomy can be avoided, as the latter intervention carries a much higher mortality and morbidity rate than lobectomy, especially after induction chemoradiotherapy. Those with persistent N2 disease after induction treatment will be given radiotherapy (11).

The reason for false negative rates has to be determined. Conventional histological sections may not be sufficiently sensitive to detect small numbers of tumor cells in regional LNs. Several studies have suggested that micrometastatic disease may be efficiently detected by immunohistochemistry (IHC). Implementation of IHC in the staging and restaging of NSCLC has yet to be investigated (21, 22).

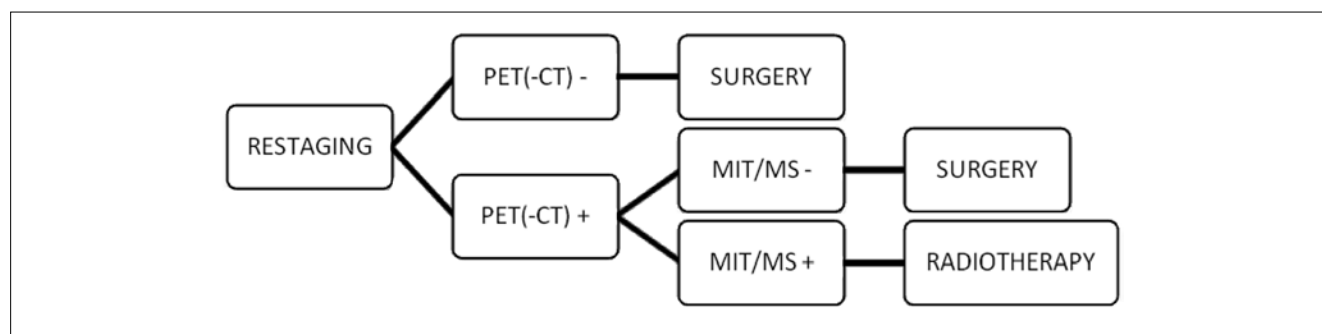
Research has been performed regarding genetic mutations in NSCLC (23-25). Epidermal growth factor receptor (EGFR) mutations and the transforming fusion gene EML4-ALK (echinoderm microtubule-associated protein-like 4 gene and anaplastic lymphoma kinase gene) may be expressed in lung adenocarcinomas.

These can be detected by IHC and are potential targets for selective kinase inhibitors targeting EGFR (gefitinib and erlotinib) and ALK (crizotinib) (26, 27). So, in specific patients newly diagnosed with adenocarcinoma, screening for EGFR mutations and EML4-ALK fusion is indicated.

Tissue remains the issue, concerning staging and certainly restaging in NSCLC. In fact, pathologic proof of downstaging is essential to select those patients who are eligible for lung surgery. Endoscopic or surgical invasive procedures may be utilized, the precise choice depending on the availability of the technique and expertise of the center. Remediastinoscopy provides us with pathological proof of response after induction therapy. In that way, it determines further treatment options and especially survival. For thoracic surgeons having no experience with reMS, an alternative approach consists of the initial use of minimally invasive staging procedures such as endobronchial or esophageal ultrasound (EBUS or EUS) to obtain a cytological proof of mediastinal nodal involvement. After induction therapy, patients are subsequently restaged by mediastinoscopy. In this way, a technically more demanding remediastinoscopy can be avoided. This approach was also found to be the most accurate in a recent review by De Cabanyes Candela et al. (28). The reliability of restaging tests after induction treatment for stage III-N2 lung cancer was reviewed and compared with pathologic findings at surgery. False negative (FN) and false positive (FP) rates for CT and PET were 33/33% and 25/33% respectively. FN rate of invasive restaging by reMS, EUS and primary mediastinoscopy were 22%, 14% and 9% respectively (28).

Also, staging and restaging has to be conducted by experienced clinicians. In that way, the opportunity for errors should be kept as minimal as possible. So, training in effective staging is essential.

In Figure 2, a general flow chart concerning mediastinal restaging after induction treatment for NSCLC is provided.



**Figure 2.** General flow chart for mediastinal restaging in NSCLC

CT: computed tomography; PET: positron emission tomography; MIT: minimally invasive technique (EBUS/EUS); MS: mediastinoscopy

## CONCLUSION

Restaging NSCLC remains a controversial issue. Downstaging of mediastinal lymph nodes determines prognosis in stage IIIA-B NSCLC. Different restaging techniques (noninvasive, minimally invasive and invasive) do exist and the level of concurrent use has still to be further explored.

Minimally invasive techniques need to be developed further. At present they are especially useful for primary staging. Mediastinoscopy and reMS provide the largest tissue samples. Although reMS is technically difficult, it remains of utmost importance as part of the restaging process.

## REFERENCES

1. Travis WD, Brambilla E, Müller-Hemerlink HK, Harris CC. Pathology and genetics of tumors of the lung, pleura, thymus and heart. In: World Health Organization classification of tumors. Lyon, IARC press; 2004:9-144.
2. Wahbah M, Boroumand N, Castro C, El-Zeky F, Eltorky M. Changing trends in the distribution of the histologic types of lung cancer: a review of 4,439 cases. *Ann Diagn Pathol* 2007;11:89-96. [\[CrossRef\]](#)
3. Edge SB, Byrd DR, Compton CC, et al. Lung. In: AJCC Cancer Staging Manual. New York, Springer; 2010:253-70.
4. Rami-Porta R, Crowley JJ, Goldstraw P. The revised TNM staging system for lung cancer. *Ann Thorac Cardiovasc Surg* 2009;15:4-9.
5. De Leyn P, Lardinois D, Van Schil PE, et al. ESTS guidelines for preoperative lymph node staging for non-small cell lung cancer. *Eur J Cardiothorac Surg* 2007;32:1-8. [\[CrossRef\]](#)
6. Toloza EM, Harpole L, McCrory DC. Noninvasive staging of non-small cell lung cancer: a review of the current evidence. *Chest* 2003;123:137-46. [\[CrossRef\]](#)
7. Fischer BM, Mortensen J, Hansen H, et al. Multimodality approach to mediastinal staging in non-small cell lung cancer. Faults and benefits of PET-CT: a randomized trial. *Thorax* 2011;66:294-300. [\[CrossRef\]](#)
8. Cerfolio RJ, Bryant AS, Eloubeidi MA, et al. The true false negative rates of esophageal and endobronchial ultrasound in the staging of mediastinal lymph nodes in patients with non-small cell lung cancer. *Ann Thorac Surg* 2010;90:427-34. [\[CrossRef\]](#)
9. Defranchi SA, Edell ES, Daniels CE, et al. Mediastinoscopy in patients with lung cancer and negative endobronchial ultrasound guided needle aspiration. *Ann thorac Surg* 2010;90:1753-7. [\[CrossRef\]](#)
10. Lally BE, Zelterman D, Colasanto JM, et al. Postoperative radiotherapy for stage II or III non-small cell lung cancer using the surveillance, epidemiology, and end results database. *J Clin Oncol* 2006;24:2998-3006. [\[CrossRef\]](#)
11. Annema JT, van Meerbeeck JP, Rintoul RC, et al. Mediastinoscopy vs endosonography for mediastinal nodal staging of lung cancer: a randomized trial. *JAMA* 2010;304:2245-52. [\[CrossRef\]](#)
12. De Leyn P, Stroobants S, De Wever W, et al. Prospective comparative study of integrated positron emission tomography-computed tomography scan compared with mediastinoscopy in the assessment of residual mediastinal lymph node disease after induction chemotherapy for mediastinoscopy-proven stage IIIA-N2 non-small cell lung cancer: A Leuven Lung Cancer Group Study. *J Clin Oncol* 2006;24:3333-9. [\[CrossRef\]](#)
13. Cerfolio RJ, Bryant AS, Ojha B. Restaging patients with N2 (stage IIIa) non-small cell lung cancer after neoadjuvant chemoradiotherapy: a prospective study. *J Thorac Cardiovasc Surg* 2006;131:1229-35. [\[CrossRef\]](#)
14. Annema JT, Veselic M, Versteegh MI, et al. Mediastinal restaging EUS-FNA offers a new perspective. *Lung Cancer* 2003;42:311-8. [\[CrossRef\]](#)
15. Krasnik M, Ernst A, Eberhardt R, Yasufuku K, Herth F. EBUS-TNA for mediastinal restaging. *Eur Resp J* 2006;28 Suppl 50:601.
16. Herth FJ, Annema JT, Eberhardt R, et al. Endobronchial ultrasound with transbronchial needle aspiration for restaging the mediastinum in lung cancer. *J Clin Oncol* 2008;26:3346-50. [\[CrossRef\]](#)
17. Rami-Porta R, Mateu-Navarro M, Serra-Mitjans M, Hernández-Rodríguez H. Remediastinoscopy: comments and updated results. *Lung Cancer* 2003;42:363-4. [\[CrossRef\]](#)
18. Stamatidis G, Fechner S, Hillejan L, et al. Repeat mediastinoscopy as a restaging procedure. *Pneumologie* 2005;59:862-6. [\[CrossRef\]](#)
19. De Waele M, Hendriks J, Lauwers P, Van Schil P. Different indications for repeat mediastinoscopy: single institution experience of 79 cases. *Minerva Chir* 2009;64:415-8.
20. De Waele M, Serra-Mitjans M, Hendriks J, et al. Accuracy and survival of repeat mediastinoscopy after induction therapy for non-small cell lung cancer in a combined series of 104 patients. *Eur J Cardiothorac Surg* 2008;33:824-8. [\[CrossRef\]](#)
21. Verhagen AF, Bulten J, Shirango H, et al. The clinical value of lymphatic micrometastases in patients with non-small cell lung cancer. *J Thorac Oncol* 2010;5:1201-5. [\[CrossRef\]](#)
22. Gu CD, Osaki T, Oyama T, et al. Detection of micrometastatic tumor cells in pN0 lymph nodes of patients with completely resected non-small cell lung cancer: impact on recurrence and survival. *Ann Surg* 2002;235:133-9. [\[CrossRef\]](#)
23. Pirker R, Herth FJ, Kerr KM, et al. Consensus for EGFR mutation testing in non-small cell lung cancer. *J Thorac Oncol* 2010;5:1706-13. [\[CrossRef\]](#)
24. Cheng H, Xu X, Costa DB, et al. Molecular testing in lung cancer: the time is now. *Curr Oncol Rep* 2010;12:335-48. [\[CrossRef\]](#)
25. Cooper WA, O'toole S, Boyer M, et al. What's new in non-small cell lung cancer for pathologists: the importance of accurate subtyping, EGFR mutations and ALK rearrangements. *Pathology* 2011;43:103-15. [\[CrossRef\]](#)
26. Rosell R, Viteri S, Molina MA, et al. Epidermal growth factor receptor tyrosine kinase inhibitors as first-line treatment in advanced non-small cell lung cancer. *Curr Opin Oncol* 2010;22:112-20. [\[CrossRef\]](#)
27. Petrelli F, Borgonovo K, Cabiddu M, et al. Targeted therapies and other agents as first-line maintenance and beyond: particular benefit in pulmonary adenocarcinoma patients. *Curr Med Chem* 2011;18:1640-50. [\[CrossRef\]](#)
28. De Cabanyes Candela S, Detterbeck FC. A systematic review of restaging after induction therapy for stage IIIa lung cancer: prediction of pathologic stage. *J Thorac Oncol* 2010;5:389-98. [\[CrossRef\]](#)